

## Cerebral Venous Sinus Thrombosis in a Pregnant Patient Presented as a Sleepy State: A Case Report Of a Complet Recovery With Anticoagulant Therapy

Mamdouh. H. Abdullah M.R.C.P, Nailya R Boulatova MD, PhD  
Abdullah M. Younes MD PhD.

---

**Abstract** a 29 – year – Old Saudi women presented with Headache and frequent attacks of vomiting. She was 8 weeks pregnant and recently discharged from the gynecology department after being treated for hyperemesis gravidarum. She was in sleepy state without focal neurological deficit. The level of consciousness was progressively deteriorating leading to coma. Protein C and Protein S levels were low. The MRI was consistent with acute cerebral venous sinus thrombosis. Heparin infusion was started, and after termination of pregnancy, it was replaced by warfarin. The patient recovered completely.

This report describes the case of the unusual presentation of cerebral sinus thrombosis as a sleepy state, headache and vomiting that may mimic hyperemesis gravidarum. The relationship between pregnancy and cerebral venous sinus thrombosis, as well as recent trends in the pharmacotherapy of this condition are discussed. From the dept. of the internal medicine, King Khaled Civillian Hospital, Tabuk, Kingdom of Saudi Arabia.

Address Correspondence and reprint request to Dr, Abdallah Younes, PO Box 961952, Sport City Circle11196. Amman, Jordan. fax: +96265339649. E-mail: [nyounes@ju.edu.jo](mailto:nyounes@ju.edu.jo)

**Key Words:** Cerebral Venous Sinus Thrombosis, Headache, Impairment of Consciousness, pregnancy, Anticoagulant therapy.

Cerebral (dural) venous sinus thrombosis (CVST) is a disease with potentially serious consequences, which usually affects young to middle aged people, the outcome of patient with CVST may vary from complete recovery to permanent neurological deficit and death. In Saudi Arabia hospital frequency was 7/10<sup>6</sup> and the relative frequency against arterial strokes

was 1:62.5<sup>2</sup>. the superior sagittal or lateral sinuses are commonly (70%) involved; and in 30% both are affected, in addition to cortical and cerebellar veins.

The etiology of CVST includes infection, dehydration, rheumatologic diseases (systemic lupus erythematosus and Behcet's disease), local trauma, and hypercoagulable states (nephrotic

syndrome, cancer, pregnancy, and oral contraceptive use)<sup>4,5,6</sup>. Hereditary prothrombotic condition such as factor V leiden (leading to increased resistance to activated protein c), Deficiency of proteins C and S and antithrombin III as well as prothrombin gene mutations may account for 10-15% of cases of CVST<sup>7,8</sup>. In up to 30% of cases no underlying cause can be identified. Among 40 CVST patients reported in the Saudi Arabia studies, Behcet's disease was the single most common etiology (25% of cases)<sup>2</sup>. We present here the cases of CSVT associated with deficiency of protein C and protein S in a pregnant patient, With atypical presentation and successfully treated with anticoagulant therapy.

**Case report.** A 29 – year – old Saudi pregnant woman presented to the emergency department with headache of 3 days duration, Described as throbbing in nature, located in the left frontal region, associated with blurring of vision, nausea and frequent attacks of vomiting, unrelated to food intake. On the day of admission she was 8 weeks pregnant. The patient was previously admitted one week before to gynecology department for hyperemesis gravidarum, improved and discharged 3 days before. She had no speech or hearing difficulties, no previous history of migraines or any other chronic illness, and no family

history of neurological disease or thrombotic disorders. She had 4 normal children delivered vaginally. Her previous pregnancies and puerperium were uncomplicated. The patient was not on any medication apart from anti emetics.

On examination, she was a febrile with a blood pressure 110/80 mm Hg, a pulse rate of 90 beats per minute, regular, and respirations 20/minute. The patient was drowsy and looked like in a sleepy state but could be aroused easily with full consciousness levels. Her neck was supple, and no other signs of meningeal irritation were present. Cardiopulmonary and abdominal examinations were unremarkable. A complete neurological exam showed no abnormalities apart from lapses of drowsiness and sleepy state. Fundus examination showed congested optic disc. The Patient was admitted to the ward for further observation and neurological assessment. Dexamethasone 4 mg was given intravenously together with mannitol 25g intravenously over 20 minutes every 6 hours. Next day she showed more deterioration of consciousness level; became more drowsy and difficult to arouse with new development of right sided weakness, more in the lower limb with upper motor neuron type, with mild right sided facial weakness. On the third day of her hospital stay the patient became comatose with

Glasgow coma scale 5/15. At that time fundus examination showed frank papilledema.

Serum protein C and Protein S levels were decreased (table). The rest of hematology, biochemistry and other routine test were normal. Antiphospholipid antibody syndrome and connective tissue disease screenings were negative.

A provisional diagnosis of CVST was considered and confirmed by MRI on the third day. The MRI showed increased signal intensity of the superior and inferior sagittal as well as the straight sinuses consistent with acute CVST (figure).

Heparin was immediately started with target aPTT 2.5 of baseline. The patient showed marked improvement starting from fourth day of anticoagulant therapy. Level of consciousness and weakness in the right side improved, the patient become ambulant with complete clearance of sensorium. Pregnancy was terminated on the sixteenth day after admission, and warfarin was given with target INR 2.5. The patient was discharged 27 days after admission without neurological symptoms. She is now regularly followed in OPD.

**Discussion:** Pregnancy and the puerperium are the periods of increased susceptibility of CVST. Significant increased risk is associated, along with other factors, with the presence of hyperemesis, infection and hypertension<sup>9</sup>.

Pregnancy is also associated with resistance to activated protein C<sup>10</sup>. Decreased level of protein C and protein S, together with hyperemesis gravidarum could be the predisposing factors to CVST in our patient. CVST associated with pregnancy and puerperium has more acute onset and a better prognosis than thrombosis due to other causes (good outcome in 80% of patient versus 58% of patient with nonobstetric causes; mortality rate 9% versus 33%)<sup>9,10</sup>. Our patient had recovered without neurological complications.

The disease is very often unrecognized at initial presentation. Extensive collateral circulation within the cerebral venous system allows for a significant degree of compensation in the early stages of thrombus formation<sup>5</sup>. In Saudi Arabia study, acute onset (<48 hours) was observed in 35% cases, sub acute (<1 month) in 40% progressive over many month in 25% cases<sup>2</sup>. The most frequent symptom of CVST is headache (up to 95% of cases)<sup>1,3,11</sup>. Focal deficits such as hemiparesis and hemisensory disturbance, seizures with or without secondary generalization, impairment of level of consciousness and papilledema occur in one-third to three-quarters of cases<sup>3,12</sup>. 20% had an isolated intracranial hypertension type picture (headache, visual disturbance and papilledema). Our

patient had subacute onset with headache, impaired level of consciousness and papilledema.

Hemorrhagic infarction occurs in approximately 10-50% of cases<sup>11,12</sup>. This is thought to be primarily due to elevated venous and capillary pressure caused by persistence of thrombosis<sup>11</sup>. The diagnosis of CVST should be confirmed by imaging studies. CT scan alone will miss a significant number of cases<sup>3</sup>). Angiography had been the accepted standard for diagnosis, however; more recently in most centers, MRI/V is the investigation of the choice for demonstrating CVST<sup>13</sup>, as it may exclude significant alternative diagnoses and will also demonstrate edema, cerebral venous infection and hemorrhage complicating cerebral venous occlusion as well as the anatomy of the disrupted venous circulation<sup>3</sup>.

Intravenous heparin is first -line treatment for CVST because of its efficacy<sup>14</sup>, safety<sup>3,12</sup>, and feasibility<sup>5</sup>. The largest partial thromboplastin time should be 80-100s. Even patients with hemorrhagic lesions benefited from intravenous heparin<sup>14</sup>. Surprisingly, in a study of anticoagulation with low molecular weight heparin followed by warfarin, there were no statistically significant advantage over placebo<sup>15</sup>.

Intravenous heparin should be followed by warfarin for 3-6 month, except those known prothrombotic

condition in which treatment may have to be life-long<sup>3,16,17</sup>.

All clinical studies of thrombolysis via selective catheterization of the occluded sinus have demonstrated excellent clinical outcome<sup>18-21</sup>. However, a recent analysis of cases treated with thrombolytics has concluded that efficacy of thrombolytics cannot be assessed from the published data<sup>23</sup>. Thus, most clinicians recommend to reserve such an aggressive and potentially dangerous therapeutic intervention only for cases of deterioration despite adequate heparinization<sup>5,6</sup>.

Other symptomatic treatments such as antibiotics, anticonvulsants, antiemetics and analgesics will depend on the circumstances. Treatment to reduce significantly raised intracranial pressure may include acetazolamide, steroids, repeated lumbar punctures, mannitol, shunt procedures and barbiturate include coma.

In conclusion, When a patient present with persistent headache and impairment of consciousness, CVST should be considered. Pregnancy has been associated with a reduced protein C and protein S levels and hypercoagulability and may predispose to CVST. In addition, vomiting, headache and sleepy state during pregnancy may mimic toxemia of pregnancy. A high index of clinical suspicion is needed to recognize

this uncommon condition so that appropriate therapy can be started. Magnetic resonance imaging with MR angiography is the method of choice in the evaluation and follow-up of CVST patients. Intravenous heparin, followed by warfarin, should be the first –line treatment, provided there are no general contraindications to its use. Heparin

## References

- 1- *De Bruijn S, de Haan R, Stam J* Clinical features and prognostic factors of cerebral venous sinus thrombosis in a prospective series of 59 patient. *J Nenrol Neurosurg Psychait* 2001; 70:105 – 108.
- 2- *Daif A, Awada A, Al – Rajeh S, Abdul-Jabbar M, Al Tahan AR, Obeid T, Malibery T* Cere-bral venous sinus thrombosis in adultd. *Storke* 1995;26:1193 – 1195.
- 3- *Ameri A, Bousser MG.* Cerebral venous thrombosis, *Neurol Clin* 1992; 10:87-111.
- 4- *Wasson J, Redenbaugh J.* Transverse sinus thrombosis, an unusual cause of headache. *Headache* 1997; 37:457 – 459.
- 5- *Allronggen H, Abbou R.* Cerebral venous sinus throm-bosis. *Postgrad Med* 2000; 76:12 – 15.
- 6- *Kimber J.* Cerebral Venous Sinus Thrombosis. *O J Med* 2002; 59;137 – 142.
- 7- *Deschiens MA, Conard J, Horrellou MH, Ameri A, Preter M, Chedro F. et al.* Coagulation studies, Factor V leiden and anticardiolipin, antibodies in 40 cases of cerebral venous thrombosis. *Stroke* 1996; 27 ; 1724 – 1730.
- 8- *Kellelt MW, Martin PJ, Enevoldson TP, Brammer C, Toh CM.* Cerebral venous thrombosis connected with 2021, a mutation of the prothro-mbin gene. *J Neurol Neurosurg Psyehiarty* 1998; 65:611 – 612.
- 9- *Lanska DJ, kryscio RI.* Risk factors for periartum and post-partum strok and infraction venous thrombosis. *Stroke* 2000; 31:1274-1282
- 10-*Candu C, Barinagarrementeria F.* Cerebral venous thrombosis associated with pregnancy and puerperium. Review of 67 cases. *Stroke* 1993; 24:1880 -1884.
- 11- *Villringer A, Mehraen S, Einhaup KM.* Pathophysiological aspects of cerebral sinus venous thrombosis. *J Neuradiol* 1994; 27:72 -80.
- 12- *Bousser MG, Chiras J, Bories J, Castagne P.* Cerebral venues

thrombosis – a review of 38 cases. *Stroke* 1985; 16:199– 213.

**13- Vogl T, Bergman C, Villringer A, Einhaupl K, Lissner J, Felix R.** Dural sinus thrombosis, value of venous MR angiography for diagnosis and follow – up. *AJR* 1994; 162:1191 – 1198.

**14- Einhaupl km, Villringer A, Meister W, Mchracin S, Garner C, Pellkofer M et al.** Heparin treatment in sinus venous throm- bosis. *Laneet* 1991; 33: 597 – 600.

**15- de Brujo F, Stam J;** for the CVT Study Group. Rando-mized, placebo – controlled trial of anticoagulant treatment with low – molecular weight heparin for cerebral sinus thrombosis. *Stroke* 1999;30:484 - 488.

**16- Bousser MG, Baranett HIM.** Dural sinus and cerebral venous thrombosis. *New Horizons* 1997; 5:332 – 41.

**17- Smith TP, Higashida RT, Barn-well SL, Halbach VV, Dowd CF, Fraser KW et al.** Treatment of dural sinus thrombosis by infusion. *J Neurouradiol* 1994; 15:801 – 807.

**18- Horowitz M, Purdy P, Unwin H.** Carlsens G 3<sup>rd</sup>. Greenlee R, Hise J et al. Treatment of dural sinus thrombosis using selective catheterization and uokinasc. *Ann Neurol* 1995; 38:58 – 67.

**19- Kim SY, Sub JH.** Direct endovascular thrombosis therapy for dural sinus thrombosis infus-ion of alltepaste. *Am J Neuror-diol* 1997; 18:639 – 664.

**20- Vilhioger A. Einhaupl KM,** Dural sinus and cerebral venous thrombosis. *New Horizons* 1997; 5:332 – 41.

**21- Frey IL, Muro GL, Mcdougall CG, Dcan BL, Jahoke HK,** Cerebral venous thrombosis combined intrathrombus PA and intravenous heparin. *Stroke* 1999; 30:489 – 494.

**22- Canbao P, Falcao F, Ferro JM.** Thrombolytics for cerebral sinus thrombosis, a systematic review. *Cerebrovase Dis* 2993; 15:159 – 166.

Table: Laboratory results

	Norinal Range	On admission
Prothrombin time, sec	11.3 – 12.9	12.8
INR		1.0
Partial thromboplastin time	21.5 – 33.5	23.5
Platelets, x 10 <sup>9</sup> /L	150 – 400	257
Anticaradialipin IgG, U/mL	< 24	4.0
Anticardiolioin IgM, U/mL	< 12	3.7
Antithrombin III. %	71.2 – 134.4	75.1
Protein C, % activity	66-0-154	52.3
Protein S,% activity	66.0-130	42.9
Lupus anticoagulant		Negative

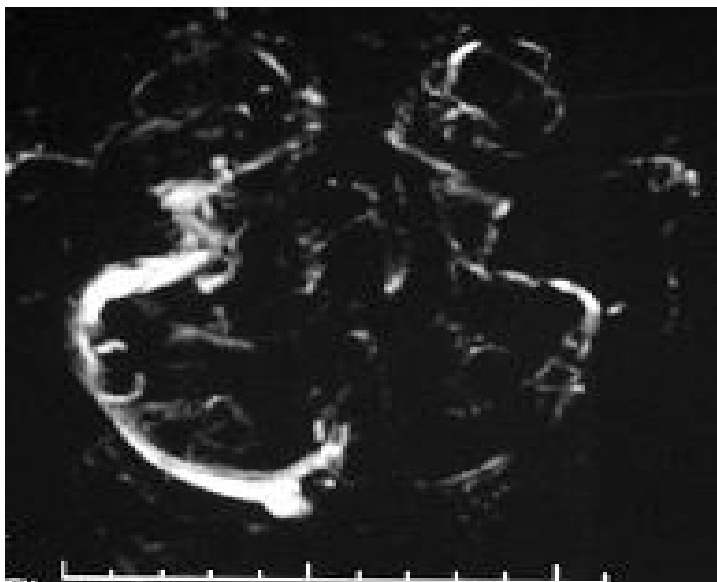


Figure – MRV – Showing filing defect in transverse and saggital sinus