Diffusion weighted imaging in acute stroke and stroke mimics: reliability analysis, radiological findings and clinical significance

Kasim Abul-Kasim MD, Ph D
Pia C Sundgren MD, Ph D
Faculty of medicine, University of Lund
Section of Neuroradiology, Department of Radiology
Malmo University Hospital
205 02 Malmo, Sweden
Corresponding author:
E-Mail : Kasim.Abul-Kasim@med.lu.se

Abstract

Background: To assess the reliability and to determine the sensitivity and specificity of Diffusion Weighted Images (DWI) in detection of acute infarcts in patients whose initial CT and conventional MR-sequences did not explain the patients stroke symptoms. The second aim was to find out if DWI provides additional information when it was performed within 2 days of onset of symptoms.

Patients and methods: MRI and DWI of 59 consecutive patients [66 % were male; aged 60 ± 14 year (Mean ± SD)] admitted with stroke and stroke like episodes were retrospectively analyzed. The images were independently evaluated by two neuroradiologists.

Results: DWI showed acute infarct in 25 patients (42 %). Hemiplegia and dizziness were the most common symptoms in patients with positive and negative DWI, respectively. Lacunar infarcts near the motor cortex were the most common type of infarcts detected by DWI. DWI provided additional information in 89 % of patients when performed within 2 days of ictus compared 31 % in patients examined ≥2 days after ictus (Fisher´s exact test, P 0.011). DWI provided relevant information in 26 % of patients despite negative DWI. The specificity and sensitivity of DWI in acute stroke was 100 % and 89 % respectively.

Conclusion: DWI is a reliable MR-sequence in the workup of acute and subacute stroke. DWI helps to differentiate acute infarcts from other white matter changes seen on conventional MRI-sequences. In patients with stroke like episodes, a negative DWI provides relevant clinical information and help in future clinical management.

Key words: stroke, stroke-like episode, MRI, DWI, lacunar infarcts.

Introduction

Diffusion weighted Imaging (DWI) is a rapid and sensitive method in the detection of infarcts in acute stroke [1–4] and plays an important role in the delineation of infarcts in the subacute stage [5–6]. DWI has been shown to be

superior to Computed Tomography (CT) and conventional T2 weighted MRI in the workup of acute stroke [1, 7].
Diffusion is the random motion of water molecules driven by their internal thermal energy. DWI is the Magnetic Resonance Imaging (MRI)-technique that is particularly sensitive to this random or "Brownian" microscopic motion. In the ischemic tissue the sodium-potassium ATPase activity in the cell membrane cease resulting in impaired membrane pump function [8] and subsequently increased water and sodium influx into the ischemic cells. The subsequent ischemic cytotoxic edema result in the decrease of the "Brownian" motion in the extracellular space. In acute stroke this will be expressed as increased signal intensity on DWI reflecting cellular edema and the decrease ADC-value reflecting restricted "Brownian" extracellular water motion.

The aims of this study were: (1) to assess the interobserver reliability of DWI in detection of acute infarcts in patients whose initial CT did not show any ischemic changes, (2) to determine the sensitivity and specificity of DWI in acute and subacute stroke, (3) to explore the ability of DWI to differentiate acute infarcts from other "unidentified bright objects" (UBOs), demonstrated by conventional MRI, and (4) to find out if DWI provide more information than did the conventional MR-sequences when it was performed within 2 days of onset of symptoms compared with DWI performed later.

Patients and methods

Medical records of all patients admitted to the acute stroke unit with stroke or stroke like episode during a three months period were retrospectively analyzed. All patients underwent non-enhanced CT on admission. Patients admitted within three hours of onset of stroke were treated with tissue plasminogen activator (tPA) and not included in the analysis of this study. Patients whose initial CT showed ischemic injuries were also excluded from further analysis. Inclusion criteria were (1) patients admitted for stroke and stroke like episodes with negative initial CT, (2) patients not fully recovered after thrombolysis, and (3) patients who were not eligible for thrombolysis e.g. patients already treated with anticoagulant therapy. A total of 59 consecutive patients were included in this retrospective analysis. Sixty sex percent (n=39) were male and 34 % (n= 20) were female. The average age was 60 ± 14 year (Mean ± SD) and range of 36-85 year. All these patients subsequently underwent MRI. The MRI included a 3-plane localizer, sagittal and axial T1W-images, T2W-images, Fluid-attenuated inversion recovery (FLAIR)-axial images, and Diffusion Weighted Images (DWI). The diffusion gradients were applied along each of the three principal directions (x, y, and z) with diffusion sensitivity (b-values) of 0, 500, and 1000 s/mm^2. Three sets of axial DWI were generated and the Apparent Diffusion Coefficient (ADC-map) was calculated. Changes in diffusion were evaluated on images with a "b-value" of 1000 s/mm^2 and on the ADC-map. All MRI were evaluated independently by two neuroradiologists. Reliability analysis of DWI to disclose acute and subacute ischemic changes was performed. The interobserver agreement with regard to DWI-findings of acute and subacute ischemic changes was determined by calculation of kappa value (κ-value). The medical records of all patients with positive DWI were further

scrutinized with respect to the neuroanatomic correlation of DWI-findings to the clinical symptoms. The time interval of MRI relative to the onset of symptoms were determined in every individual patient and patients were then categorized into two groups depending on whether MRI were performed within 2 days of the onset of symptoms (group 1) or ≥ 2 days after the ictus (group 2). We hypothesized that DWI would provide more additional information than did the conventional MR-sequences when it was performed within 2 days of onset of symptoms. To test this hypothesis SPSS automatically computes chi-square test and/or Fisher's exact test. Differences with a P value ≤ 0.05 were considered statistically significant. All statistical analysis was performed in SPSS 15.

Results

The two observers agreed about the findings of DWI in all the 59 examinations included in the analysis. This resulted in a total interobserver agreement (κ-value of 1). In 34 patients (58 % of study population) neither DWI nor the conventional MRI revealed abnormalities that explain the symptoms the patients were admitted for. Out of these 34 patients, 9 patients had the diagnosis TIA. The patient's symptoms and their final diagnosis at discharge from stroke unit are shown in Table 1.

DWI was positive in the remaining 25 patients (42 % of study population) and showed infarcts in regions responsible for the symptoms. The symptoms the patients with positive DWI had been admitted for are shown in Table 2.

Diagnosis	N
1. Cerebral ischemia: Total	**3**
Slight paresis right arm. CT and MR performed the same day. Moved to other hospital	1
Dysarthria, paresis right arm: Amphetamine spasm	1
Dysesthesia and apraxia left hand and facial palsy	1
2. TIA: Total	**9**
3. Non-ischemic; Total	**22**
Dizziness only	11
Dizziness with hearing loss and headache	2
Syncope	1
Hearing loss: alone or with tinnitus and headache	2
Myelitis	1
Migraine	1
Postictal	1
Confusion associated with pneumonia	1
Functional	1
Dysphagia	1
Total	**34**

Table 1: Symptoms and final diagnosis of patients with negative DWI. N: Number of patients.

Symptoms	Number
Hemiparesis	13
Facial palsy	8
Dizziness in combination with other symptoms	5
Arm paresis	4
Sensory loss	4
Dysarthria	4
Visual disturbance	3
Ataxia	3
Headache in combination with other symptoms	3
Aphasia	2
Confusion	2

Table 2: Symptoms in patients with positive DWI.

Hemiparesis was the most common symptom followed by facial palsy.
Dizziness as the only presenting symptom was reported in 11 patients with negative DWI (Table 1) but not in any of the patients with positive DWI.
The locations of the infarcts found on DWI are shown in Table 3.

Symptoms	Number
Cortical and subcortical around central sulcus	10
Internal capsule	6
Corona radiata	5
Thalamus	4
Brain stem	3
Cerebellum	2
Cortical and subcortical lobar infarcts:	
Occipital lobe	3
Temporal lobe	2
Frontal lobe	1
Parietal lobe	1

Table (3): Anatomical distribution of different infarcts seen on DWI.
*The number of infarcts detected was 37 in 25 patients with positive DWI; 7 patients had multiple embolic infarcts.

Cortex and the subcortical white matter around central sulcus (affecting motor area, sensory area or both) was the most common site affected.
In 13 patients the infarctions were lacunar whereas in 7 patients the infarctions were multiple embolic. The specificity and the positive predictive value (PPV) of DWI were 100 %, the sensitivity was 89 % and the negative predictive value (NPV) was estimated to 88 % (Table 4). According to time interval of MRI relative the onset of patients symptoms, the patients with positive DWI (n=25) were categorized into group 1 (n= 9) in which MR-examinations were performed within 2 days of symptom (mean 16 hours and range 1-36 hours) and group 2 (n= 16) in which MR-examinations were performed ≥ 2 days after the onset of stroke (mean 2.8 days and range 2-6 days). The patient in group 1 who was admitted within 1 hour after the onset of symptom had atrial fibrillation treated with oral anticoagulant therapy which rendered him non-eligible for treatment with tPA.

DWI	Cerebral ischemia		
	Yes	No	Total
Positive DWI	25	0	25
Negative DWI	3	22	25
Total	28	22	50

Table 4: Sensitivity, specificity, PPV and NPV of DWI in acute and subacute ischemic stroke
*Sensitivity 89 %, specificity 100 %, PPV 100 %, and NPV 88 %
**The numbers shown are patient's number. Nine patients were considered to have TIA with no established ischemic injury.

DWI provided additional information not seen on conventional MR-sequences in 8 patients (89 %) in group 1 compared to 5 patients (31 %) in group 2. This difference was statistically significant (Fisher´s exact test, P 0.011).

DWI also provided additional relevant information in 9 patients (26 %) despite negative results on DWI because these patients had large number of UBOs. Without DWI it would have been impossible for the observers to exclude lacunar infarcts in one or more of these white matter changes.

All patients with hemiplegia showed infarcts in different parts of motor cortex. None of patients with dizziness alone showed acute infarct on DWI. Figure 1 and 2 shows MRI of two different patients with positive DWI whereas Figure 3 shows MRI in patient with TIA and negative DWI.

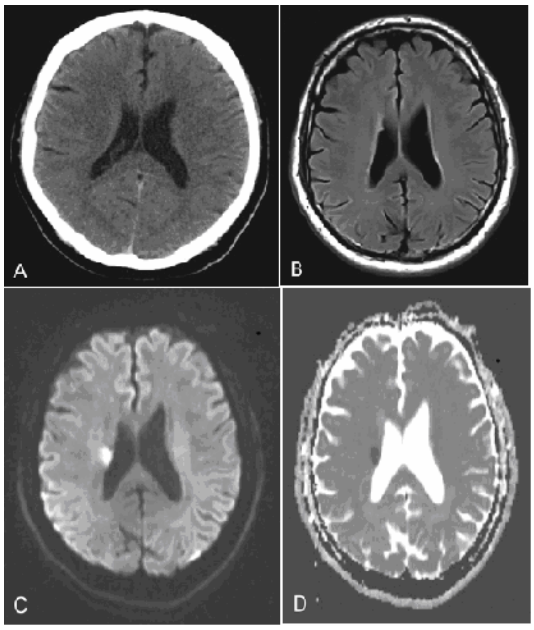

Figure (1): (A–D): 62 year old man with hypertension admitted 1.5 hour after the onset of left sided hemiplegia. CT (A) was normal. The patient treated with tPA with no significant improvement of hemiplegia. MRI performed 4.5 hours after ictus showed no abnormality on FLAIR (B), increased signal intensity on DWI in the corticospinal tract at the level of corona radiata (C), and markedly decreased ADC-value (D) of the same region suggestive of acute lacunar infarction.

Discussion

In accordance with other studies [2, 3, 6, 9] this study has shown that DWI is a reliable method with regard to delineation of acute and subacute ischemic changes not visible on CT or conventional MR-sequences and thus plays an important role in the workup of acute and subacute stroke.

One of the major advantages of DWI is the short acquisition time which varies depending on the manufacturer of the MR-scanner (e.g. 55 seconds in Siemens).

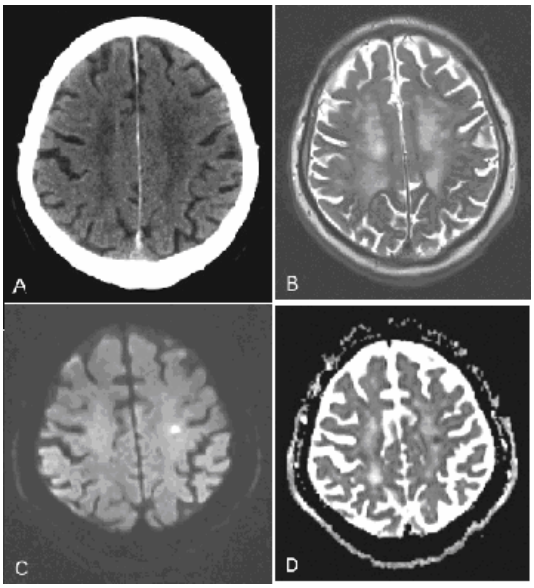

Figure (2): (A–D): 85 year old man with coronary artery disease presented to acute stroke unit 18 hours after the onset of right sided hemiplegia and dizziness. CT (A) showed wide spread white matter changes. MRI performed 2.5 days after ictus showed sever confluent hyperintensity of the white matter. T2-weighted images (B) could not distinguish a separate acute ischemic change. DWI and ADC (C, D) revealed an acute lacunar cortical and subcortical infarction near the precentral gyrus.

We have in this study also shown that DWI provide significant radiological information in addition to those seen on conventional MR sequences especially within the first 2 days after the onset of stroke. However, in the 5 patients (31 %) examined ≥ 2 days after the onset of stroke, DWI provided additional information helping to differentiate lesions responsible for the symptom from other non- symptomatic UBOs. In addition DWI helped to rule out the occurrence of acute lacunar infarcts in 9 patients with negative DWI who had white matter UBOs.

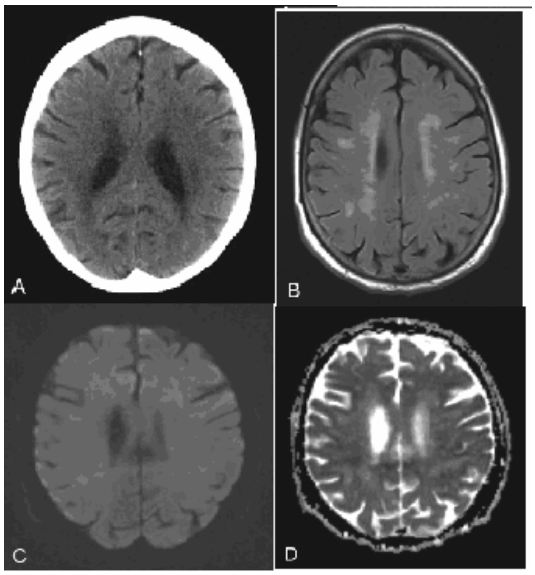

Figure (3): (A–D): 75 year old women admitted > 6 hours after the onset of numbness, paraesthesia and weakness of the left arm. CT (A) was normal. 2.5 days after the onset of symptoms MRI was performed because of persistent paraesthesia of the left arm and fluctuating weakness of the left arm and leg. Large number of UBOs was identified in the white matter on FLAIR (B) but no changes in signal intensity on DWI (C) or ADC-value (D) suggestive of acute/subacute ischemia. Diagnosis at discharge was transient ischemic attack (TIA). Carotid artery doppler ultrasonography showed stenosis of right internal carotis artery.

Despite negative DWI, three of patients with persistent neurological deficit were regarded to have cerebral ischemia (Table 1). Negative DWI in patients with ischemic episodes has been described and believed to depend on concomitant perfusion abnormality that is symptomatic but yet is not sever enough to cause DWI abnormality [10]. These false negative DWIs in our three patients resulted in drop of the sensitivity and negative predictive value of DWI to 89 % and 88 % respectively. Together with 25 patients with positive DWI, these three patients were regarded having the diagnosis "cerebral ischemia". With nine patients having the diagnosis TIA on discharge (with negative DWI), the total number of patient who sustained an episode of cerebrovascular incident increased to 37 (63 % of study population). This mean that stroke mimics constitute 37 % of the patients (n=22) admitted to the acute stroke unit at our institution. Unlike other studies which focus mainly on the positive findings of DWI, our study also included analysis of the clinical and radiological outcome of patients with negative DWI. Categorization of patients of this study into patients with stroke and stroke like episodes (stroke mimics) influenced the future management of these patients. The vast majority of patients with stroke like episodes were referred to ear, nose and throat clinics for further evaluation with regard to the etiology of dizziness, hearing loss and dysphagia. Dizziness alone is seldom a sign of acute stroke and generally do not necessitate any further radiological investigation. On the other hand patients with the diagnosis TIA were initially planned for carotid doppler ultrasonography and echocardiography. Patients with embolic infarcts were planned for trans-esophageal ultrasound as well. These measures proved to have impact on the long term outcome of patients with stroke or stroke like episodes. DWI particularly in combination with perfusion studies has been shown to predict the outcome in ischemic stroke [11].

Conclusion

DWI is a reliable technique in the workup of acute and subacute stroke with 100 % specificity and PPV and with high sensitivity and NPV. DWI showed to be able to differentiate acute infarcts from other UBOs demonstrated by conventional MRI and provide more information than did the conventional MR-sequences, when it was performed

within 2 days of onset of symptoms compared with DWI performed later. However, a negative DWI also provides important and relevant clinical information especially in patients with white matter changes. DWI might help in clinical decision making with regard to the future management of patients with stroke or stroke like episodes (stroke mimics).

References

1-Singer MB, Chong J, Lu D, Schonewille WJ, Tuhrim S, Atlas SW. Diffusion-weighted MRI in acute subcortical infarction. Stroke1998; 29:133-6.

2-van Everdingen KJ, van der Grond J, Kappelle LJ, Ramos LM, Mali WP. Diffusion-weighted magnetic resonance imaging in acute stroke. Stroke 1998; 29:1783-90.

3-Geijer B, Brockstedt S, Lindgren A, Ståhlberg F, Norrving B, Holtås S. Radiological diagnosis of acute stroke. Comparison of conventional MR imaging, echo-planar diffusion-weighted imaging, and spin-echo diffusion-weighted imaging. Acta radiol 1999; 40:255-62.

4-Li TQ, Chen ZG, Hindmarsh T. Diffusion-weighted MR imaging of acute cerebral ischemia. Acta radiol 1998; 39:460-73.

5-Geijer B, Lindgren A, Brockstedt S, Ståhlberg F, Holtås S. Persistent high signal on diffusion-weighted MRI in the late stages of small cortical and lacunar ischaemic lesions. Neuroradiology 2001; 43:115-22.

6-Augustin M, Bammer R, Simbrunner J, Stollberger R, Hartung HP, Fazekas F. Diffusion-weighted imaging of patients with subacute cerebral ischemia: comparison with conventional and contrast-enhanced MR imaging. AJNR 2000; 21:1596-602.

7-Weber J, Mattle HP, Heid O, Remonda L, Schroth G. Diffusion-weighted imaging in ischaemic stroke: a follow-up study. Neuroradiology. 2000; 42:184-91.

8-Mintorovitch J, Yang GY, Shimizu H, Kucharczyk J, Chan PH, Weinstein PR. Diffusion-weighted magnetic resonance imaging of acute focal cerebral ischemia: comparison of signal intensity with changes in brain water and Na+, K (+)-ATPase activity. J Cereb Blood Flow Metab 1994; 14:332-6.

9-Gonzales RG, Schaefer P, Buonanno F, et al. Diagnostic accuracy of diffusion MRI in patients scanned within 6 hours of stroke symptom onset. Radiology 1999; 210:155–162.

10-Ay H, Buonanno FS, Rordorf G, Schaefer PW, Schwamm LH, Wu O, Gonzalez RG, Yamada K, Sorensen GA, Koroshetz WJ. Normal diffusion-weighted MRI during stroke-like deficits. Neurology 1999; 52:1784-92.

11-Warach S, Dashe J, Edelman R. Clinical outcome in ischemicstroke predicted by early diffusion-weighted and perfusion magnetic resonance imaging: a preliminary analysis. J Cereb Blood Flow Metab 1996; 16:53–59.