Case Report

Microfilaria in fine needle aspiration cytology of breast lump: An unusual finding

Subrata Pal[1], Kingshuk Bose[2]

[1]Department of Pathology, Shristi Diagnostic Centre, [2]Department of Pathology, Bankura Sammilani Medical College, Bankura, West Bengal, India

ABSTRACT

Filariasis is a common health problem in India. Lymphatic filariasis is mostly caused by *Wuchereria bancrofti* and *Brugia malayi*. Microfilariae are often found in cytology smears from swelling at various sites and it is rarely associated with neoplasms. However, filarial breast nodule is a very rare finding even in an endemic region. Here, we present a rare case of filarial breast lump diagnosed by fine needle aspiration cytology.

Keywords: Breast lump, cytology, microfilaria

INTRODUCTION

Filariasis is a chronic disabling parasitic disease, prevalent in south Asia and Africa.[1,2] In India, filarial infections are commonly caused by two closely related nematodes – *Wuchereria bancrofti* and *Brugia malayi*.[1,3] It is more prevalent in the coastal areas and river banks of India.[2,4] The disease follows a chronic course and mainly affects the lymphatics of lower limbs, spermatic cord and epididymis, retroperitoneal lymphatics, etc.[1] Breast is a rare site of the filarial lesion.[4] Till now only a few cases have been reported in the English literature. We present a rare case of filariasis of the breast, diagnosed by fine needle aspiration cytology (FNAC).

CASE REPORT

A 32-year-old woman presented with complaints of a painless breast lump for 3 weeks. The patient had no history of fever, anorexia, weight loss or nipple discharge. On examination, she was average built, and general examination of the breast revealed a 3 cm diameter, firm mobile, breast lump at the lower and outer quadrant of the right breast. No nipple retraction or skin changes (peau d'orange) were seen during examination of the breast lump, and no axillary lymph nodes were palpable in the ipsilateral and contralateral side. Routine blood examinations and biochemistry were within normal limits. On ultrasound examination, a 3 cm nodular hypoechoic lesion was revealed at the lower outer quadrant of right breast. Fine needle aspiration was done to evaluate the nature of the lesion. Aspiration was done by a 23 G needle attached with a 10 ml syringe, the smears from the aspirated material were stained by May-Grunwald-Giemsa and Leishman-Giemsa stain. Light microscopical examination of the stained smears showed plenty of inflammatory cells (eosinophils, neutrophils, lymphocytes and histiocytes) admixed with a fair number of benign duct epithelial cells and many sheathed microfilaria of *W. bancrofti* species [Figures 1-3]. We diagnosed the case as filarial breast lump on the basis of cytomorphology.

She was treated with diethylcarbamazine (DEC) for 3 weeks, and the lesion reduced rapidly in 2 weeks and resolved completely within a month.

Address for correspondence:
Dr. Subrata Pal, Gobinda Nagar, Kenduadihi, Bankura, West Bengal, India.
E-mail: subratapal1985@gmail.com

Access this article online

Quick Response Code:

Website: www.thejhs.org

DOI: 10.4103/1658-600X.166491

How to cite this article: Pal S, Bose K. Microfilaria in fine needle aspiration cytology of breast lump: An unusual finding. J Health Spec 2015;3:235-7.

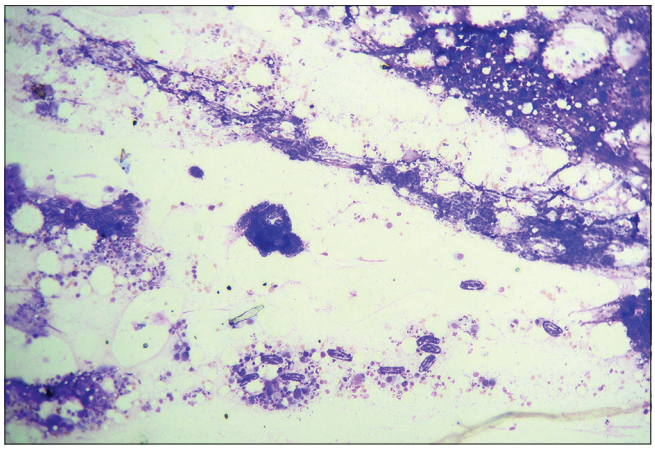

Figure 1: Cytology of aspirate from breast nodule reveals many microfilariae in the background of inflammatory cells (L and G stain, ×10 view)

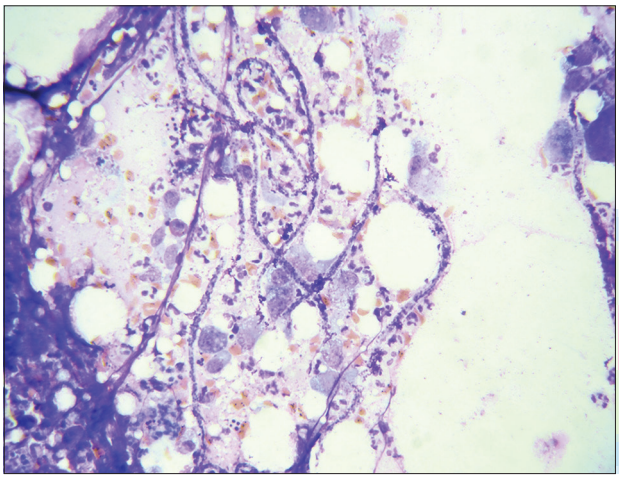

Figure 2: Cytology smear reveals plenty of sheathed microfilariae in the background of inflammatory cells (L and G stain, ×40 view)

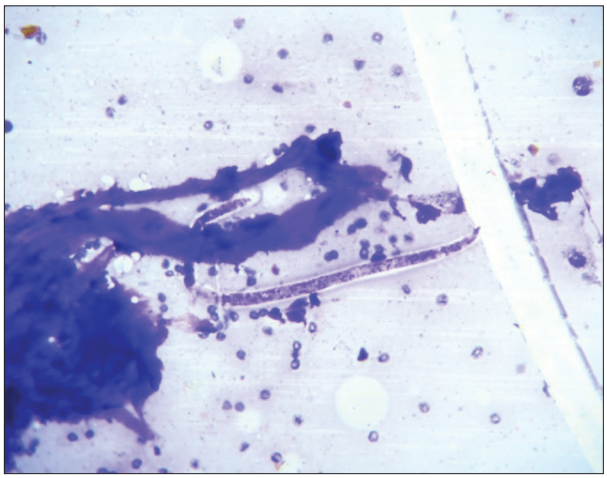

Figure 3: Reveals intact species of *Wuchereria bancrofti* in aspirate from the breast nodule (L and G stain, ×40 view)

DISCUSSION

Filariasis is a major public health problem in the tropical countries of Asia and Africa.[1,2] In India, filariasis is an endemic disease, and most of the cases are caused by *W. bancrofti* and *B. malayi*.[2,3] *W. bancrofti* accounts for about 90% of all cases of filariasis all over the world and it is commonly found along the sea coasts and river banks in India.[2,4] In contrast, *B. malayi* are mainly encountered in South India, Sri Lanka and Far East.[4] Among the eight species of filarial parasites, the main burden of filarial infection was on the lymphatic systems of the lower limbs, spermatic cord and epididymis and retroperitoneal tissue.[1] Microfilariae have been infrequently reported from body fluids (pleural, pericardial and hydrocele) bronchial aspirates, cervicovaginal smears and thyroid aspirates.[1,4] However, filariasis involving breast is a rare occurrence, and very few cases have been reported in the English literature.[1-3]

Filarial breast lesions present with nodular firm hard mass often mimic neoplastic lesions in clinical examination.[1] We encountered similar diagnostic dilemma in clinical evaluation. Among the reported cases, filarial breast nodules were commonly found at the upper outer quadrant of the breast.[2] However, in our case, we found the lesion at the lower outer quadrant of the breast. FNAC is a well-established, widely available, simple and effective means to evaluate neoplastic and nonneoplastic causes of breast lump.[3] Cytomorphology of the breast's filarial nodule showed clusters of benign duct epithelial cells, mixed inflammatory cells (polymorphs, lymphocytes and histiocytes) and microfilarial worm.[2,3,5] In some cases, granuloma formation may also be found.[2] Filarial breast nodule is possibly due to filarial lymphangitis which follows chronic inflammation and fibrosis due to disrupted lymphatic vessels.[2]

Both in bancroftian and brugian filariasis, man is the definitive host and mosquito is the intermediate host.[1] In India, female *Culex pipiens* fatigans were the vector of bancroftian and brugian filariasis.[6,7] Third stage larvae of developing *W. Bancrofti* and *B. malayi* are the infective form, which inoculates through skin during mosquito bites.[6,7] The deposited larvae puncture or penetrate through the skin and invade to subcutaneous lymphatics to reache areas where they can grow.[6] Diagnosis of filarial lesions depends on the demonstration of microfilaria in the blood, body fluids or tissue aspirates. Species identification is often difficult in the adult worm, but it is possible on the basis of microfilarial morphology.[1,4,7] Main differentiating features include - length (large in *W. bancrofti*), secondary kinking (found in *B. malayi*) versus smooth curves (*W. bancrofti*), tale tip (free of nuclei in *W. bancrofti*, two discrete nuclei in *B. malayi*).[1,4,7] On

the basis of morphology, our case was a *W. bancrofti* infection.

Our case was a unique representation of filarial breast nodule mimicking neoplastic breast lump. FNAC resolved the diagnostic dilemma and helped avoid unnecessary surgery. Another peculiarity was that peripheral blood eosinophil count in our case was normal, whereas some of the previously reported cases were associated with peripheral blood eosinophilia.[1,8] Treatment with DEC is effective in resolving filarial breast nodule, as seen in our case.

CONCLUSION

Filarial breast nodule is rare, and it often mimics a neoplastic breast lesion. FNAC is a very effective diagnostic tool in the diagnosis of filarial breast lesion and it helps avoid unnecessary surgical procedure. It should be considered as a differential diagnosis for short-lasting nodular breast lump, especially in countries like India, where filariasis is an endemic disease.

Acknowledgment

We would like to thank Prof. (Dr.) Manaj KR Chowdhuri for his kind co-operation.

Financial support and sponsorship

Nil.

Conflicts of interest

There are no conflicts of interest.

REFERENCES

1. Kaur R, Philip KJ, Masih K, Kapoor R, Johnny C. Filariasis of the breast mimicking inflammatory carcinoma. Lab Med 2009;40:683-5.
2. Dayal A, Selvaraju K. Filariasis of the breast. Webmed Cent Surg 2010;1:WMC00942.
3. Khan R, Harris SH, Maheshwari V. Filarial breast mouse. J Coll Physicians Surg Pak 2011;21:513.
4. Bhardwaj S, Mahajan D, Attri MR. Filariasis of the breast. JK Sci 2007;9:98-9.
5. Singh NG, Chatterjee L. Filariasis of the breast, diagnosed by fine needle aspiration cytology. Ann Saudi Med 2009;29:414-5.
6. Sujathan K, Elizabeth AK. Breast lump suspected for carcinoma diagnosed as filarial granuloma by FNAC: A report of two cases. Aust Asian J Cancer 2005;4:57-9.
7. Chatterjee KD. Phylum nemathelminthes, class *Nematoda*. In: Parasitology (Protozoology and Helminthology). 13th ed. Kolkata: Chatterjee Medical Publishers; 2009. p. 199-258.
8. Chowdhary M, Langer S, Aggarwal M, Agarwal C. Microfilaria in thyroid gland nodule. Indian J Pathol Microbiol 2008;51:94-6.