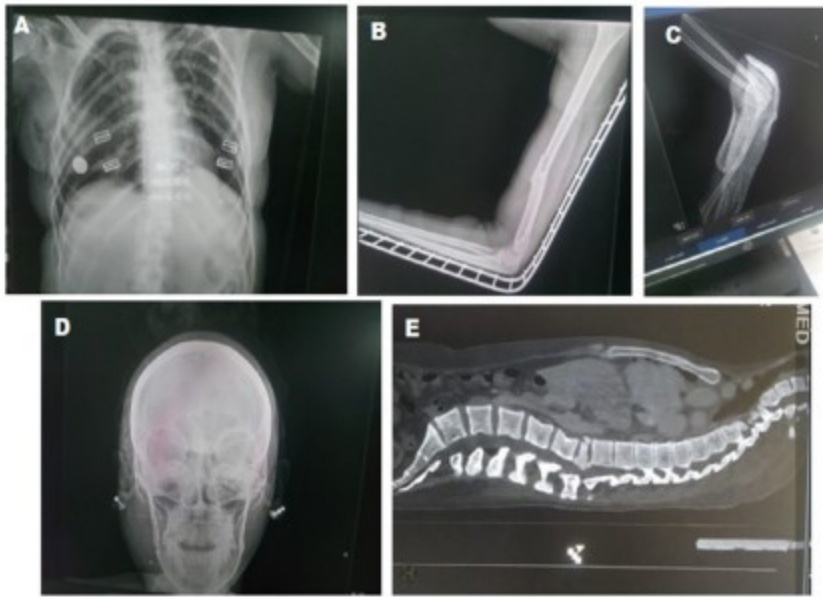


Figure 1. Patient's x-ray before and after the first operation

Before



After

