

*Case report***Diffuse calcification of a transplanted kidney: a manifestation of renal osteodystrophy***Hesham Jaber,¹ Asem Hiari,¹ Rula Jmea'n¹ and Muna Nemri¹***Case history**

A 17-year old male patient presented with uraemic symptoms in August 1991. Physical examination was unremarkable apart from pallor and uraemic smell. He was admitted with the following findings: packed cell volume 23, calcium 9.1 mg/dl, phosphate 10.5 mg/dl, creatinine 11.5 mg/dl, blood urea nitrogen 124 mg/dl, sodium 134 mg/l, potassium 4 mg/l, glucose 96 mg/dl, alkaline phosphatase 898, albumin 40g/l, protein 70g/l. Renal ultrasound showed two small atrophic hyperechoic kidneys and glomerular filtration rate 6 ml/min. A subclavian catheter was inserted and the patient was started on regular haemodialysis twice weekly. The patient was prescribed calcium carbonate 500 mg tablet, three times daily, alfacalcidol 0.25 g once daily and folic acid one 5 mg tablet daily. In September 1992 he was admitted for a live related kidney transplant from his cousin which was complicated by accelerated rejection for which he was given intravenous methyl prednisolone 1 g for 3 days; he was maintained on cyclosporin 2 cm³ twice a day, Imuran 50 mg twice a day and prednisolone 60 mg a day to be tapered over the following 6 weeks. The patient continued to have reduced urine output with high levels of creatinine around

10 mg/dl over the following 6 months. Immunosuppressive drugs were discontinued and he was put back on dialysis.

The patient was admitted again in 1994 with generalized bone aches, myalgia and difficulty in walking. On examination he was anaemic with blood pressure 150/90 supine; the chest had barrel shaped deformity with fine basal crackles and the heart had mitral regurgitation murmur. Abdominal examination was unremarkable, upper limbs showed pseudoclubbing and lower limbs showed atrophic muscles with decreased power to 3/5; there was no sensory deficit.

Laboratory results were as follows: creatinine 13 mg/dl, calcium 7 mg/l, alkaline phosphatase 1200, parathyroid hormone level 1200 mg/ml. Neck ultrasound showed bilateral parathyroid gland enlargement suggestive of hyperparathyroidism. X-ray skeletal survey showed renal osteodystrophy.

Discussion

The patient was suffering from chronic renal failure with its reported clinical picture, laboratory results and radiological changes. The pathophysiology of renal os-

¹ King Hussein Medical Centre, Amman, Jordan.

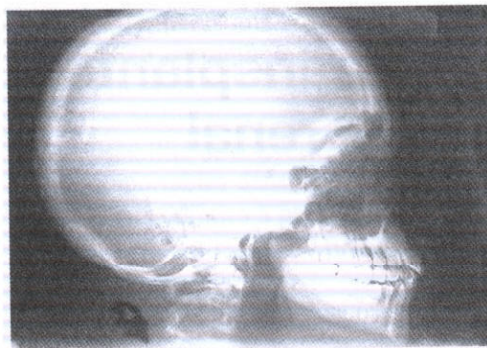

Figure 1 Skull X-ray: shows pepper pot appearance with generalized osteopenia

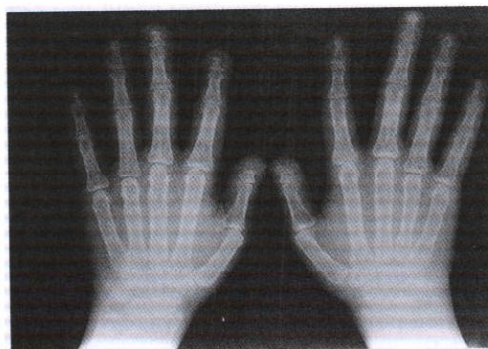

Figure 2 Hand X-ray: shows subperiosteal bone erosions of the phalangeal shafts and erosions of the terminal tufts

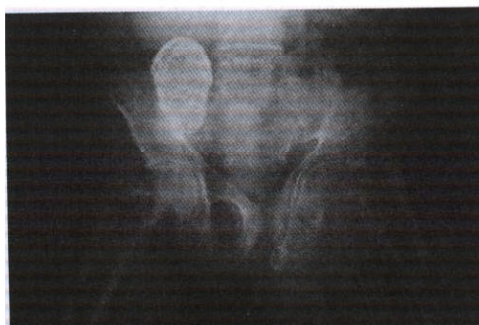

Figure 3 Pelvic X-ray: shows a calcified transplanted kidney in the right side of the pelvis, with triradiate pelvic deformity associated with left protusio acetabuli

teodystrophy, i.e. osteomalacia and hyperparathyroidism, worked to increase the blood calcium and phosphate levels [1,2]. The patient had secondary hyperparathyroidism prior to kidney transplant, and we hoped all the biochemical changes would be corrected following transplantation. Unfortunately, the transplanted kidney was rejected and he continued to have renal failure with renal osteodystrophy; the transplanted kidney became calcified and ceased to function, a picture seen in renal tuberculosis before the era of tuberculosis antibiotics. We reviewed the literature [3-7] and found no mention of such a complication in transplanted kidneys. However, we ruled out the possibility of renal tuberculosis especially in such an immunocompromised patient. The ascitic, pleural and pericardial fluid cultures were all negative for acid bacilli. We conclude that renal osteodystrophy can lead to diffuse calcification of a transplanted kidney.


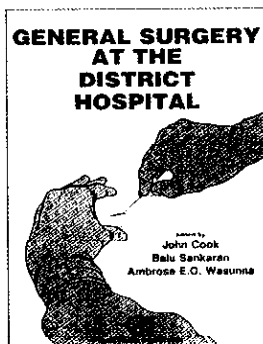
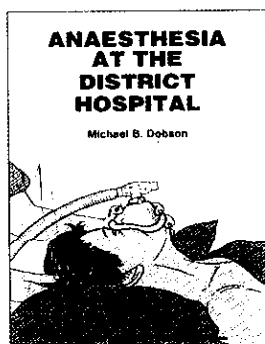
References

1. Volger JB, Genant HK. Metabolic and endocrine disease of the skeleton. In: Grainger and Allison. *Diagnostic radiology* 2nd ed., Edinburgh, Churchill Livingstone, 1991, 78:1613-1615.
2. Greenfield GB. *Radiology of bone diseases: renal osteodystrophy*, 5th ed. Philadelphia, Lippincott-Raven Publishers, 1990, 2:62-72.
3. Murray RO, Jacobson HG. *The radiology of skeletal disorders, metabolic and endocrine disorders, renal osteodystrophy* 2nd ed., Edinburgh, Churchill Livingstone, 1977, 682-685.
4. Ritz E et al. Dialysis bone disease. *Proceedings of the European Dialysis and Transplant Association*, 1971, 8:131-36.

5. Simpson W et al. Skeletal changes in patients with regular hemodialysis. *Radiology*. 1973. 107: 313-320.
6. Shapiro R. Radiological aspects of renal osteodystrophy. *Radiology clinicians of North America*, 1972, 10:567-568.
7. Lee DBN, Goodman WG, Goburn JW. Renal osteodystrophy. Some new questions on an older disorder. *American journal of kidney diseases*, 1988, 11:365

SURGERY AND ANAESTHESIA AT THE DISTRICT HOSPITAL

A series of three handbooks
that can help doctors acquire safe, standardized
— and life-saving — surgical skills



These publications can be ordered from Distribution and Sales Unit, World Health Organization, 1211 Geneva 27, Switzerland. Telephone: (22) 791 2476; Fax: (22) 791 4857.

Price: *Anaesthesia at the District Hospital* Sw.fr. 20.- / US\$ 18.00 (In developing countries: Sw.fr. 14.-). *General Surgery at the District Hospital* Sw.fr. 30.- / US\$ 21.00 (In developing countries: Sw.fr. 21.-). *General Surgery at the District Hospital* Sw.fr. 25.- / US\$ 22.50 (In developing countries: Sw.fr. 17.50.-).