

## Case report

# Non-neoplastic gastrojejunal fistula in a 68-year-old male patient

W.I. Treef<sup>1</sup>

## Introduction

Non-neoplastic gastrojejunal fistula is a rare condition which can develop after vagotomy and gastroenterostomy [1]. Gastrojejunal fistula more often follows simple gastroenterostomy than partial gastrectomy. The main factor which produces rapid deterioration of the patient is fouling of the jejunum by colonic contents, which results in disturbances in the vital absorptive mechanisms [2].

## Case report

A 68-year-old male Jordanian patient was admitted to Princess Haya Hussein Hospital for evaluation of diarrhoea of 6 months duration, associated with weight loss and vomiting which was feculent in nature. In 1982, the patient had undergone a truncal vagotomy and gastrojejunostomy for peptic ulcer. There was a history of recurrent admission to hospital for gastroenteritis which had been treated accordingly. He was a chronic smoker.

Physical examination revealed an upper midline scar in the thin abdomen that moved with respiration. There was tenderness localized to the mid-abdomen on deep palpation. There were no palpable masses, the

bowel sounds were normal and *per rectum* examination revealed nothing abnormal.

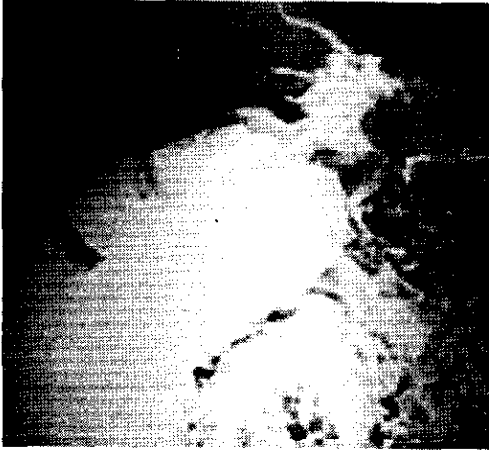
Radiological examination with barium enema indicated a gastrojejunal fistula. (Figures 1 and 2).

After good preoperative preparation, one-stage resection was performed. The affected portion of the jejunum was resected, reanastomosis of the jejunum carried out

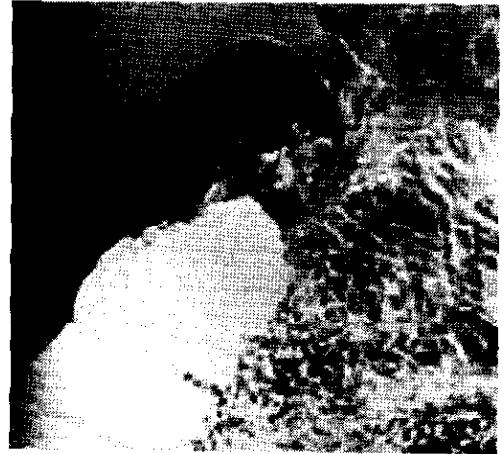

Figure 1 Fistula connecting the superior border of the hepatic flexure of the transverse colon with the small bowel and stomach

<sup>1</sup> Department of General Surgery, King Hussein Medical Centre, Amman, Jordan.  
Received: 23/09/97; accepted: 08/03/98



**Figure 2 Barium refilling the colon, small bowel and stomach through the fistula**

and the colonic opening was closed. The patient had a smooth recovery and was discharged after 10 days in good general health.

The pathological report showed small intestine with congestion oedema and increased mononuclear cell infiltrate. There was no evidence of malignancy.

## Discussion

The etiology of a fistula between the stomach and the colon varies. The development of an anastomotic ulcer following gastric surgery for benign peptic ulcer disease is the commonest cause of gastrojejuno-colic fistula [3,4]. This complication was more common in the early part of this century when gastroenterostomy was the treatment of choice for peptic ulcer disease. The most frequent symptoms are diarrhoea, weight loss and vomiting, frequently feculent in na-

ture [3]. The diagnosis is best confirmed by a barium enema examination, which gives good results.

The complications of established gastric or intestinal fistula include electrolyte abnormalities and malnutrition, sepsis, intraperitoneal abscess, wound infection and pancreatitis. Without parenteral nutrition, the nutritional status of patients with fistula inevitably deteriorates because of the loss of proteins and electrolytes through the fistula, and the inability of the patient to eat.

Over a period of 16 years, Spivak and his colleagues performed 423 operations on patients with peptic ulcer of anastomosis. In 13 of them, the condition was complicated by gastrointestinal-colonic fistula. Out of 7 patients operated upon in the first 11 years, 4 patients died (because of one or more of the above-mentioned complications). Out of 6 patients operated upon during the second period (the last 5 years), there were no deaths [5].

The low mortality was due to less traumatic operations and adequate pre-operative preparation of the patients.

In our patient, the gastrojejuno-colic fistula was due to a benign inflammatory process, and was treated successfully by a single surgical intervention.

## Conclusion

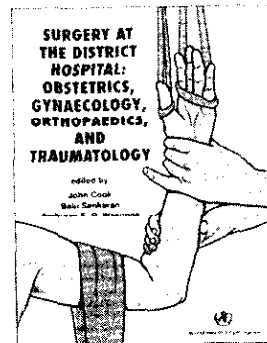
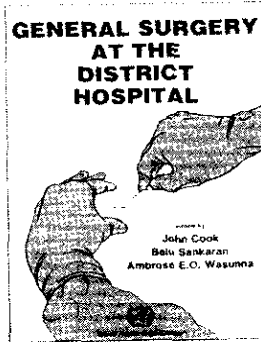

The sudden onset of diarrhoea in a patient who has undergone vagotomy with gastrojejunostomy must raise the possibility of a gastrojejuno-colic fistula. One-stage resection with reanastomosis is a safe procedure in the treatment of gastrojejuno-colic fistula and has a low mortality rate, especially when the patient has good preoperative preparation and modern suture techniques are used.

## References

- Galbiati E, Figliuzzi M, Baiocchi C. La fistola gastrodigiunocolica non-neoplastica. Presentazione di 3 casi. [Non-neoplastic gastrojejuno-colic fistula. Presentation of 3 cases.] *Minerva chirurgica*, 1980, 35:271-7.
- Bailey and Love's short practice of surgery*, 19th ed. Aylesbury, Buckinghamshire, Hazell, Watson and Viney Limited, 1984:811-4.
- Senechoud C, Brugger JJ, Jacot C. Diarrhees et vomissements fecaloïdes recidivants chez un patient de 56 ans. [Diarrhea and recurrent vomiting of fecal matter in a 56-year old patient]. *Schweizerische rundschaufur medizinin praxis*, 1990, 79:1575-7.
- McCullough KM, Gregson R. Spontaneous healing of gastrocolic fistula due to benign gastric ulcer. *Clinical radiology*, 1987, 38(4):431-3.
- Spivak VP. Puti snizheniia letal' nosti bol'nykh zheludochno-tonko-tolstokish-echo fistuloi. [Ways of reducing mortality in patients with gastric and small and large intestine fistulas.] *Vestnik khirurgii imeni I.I. Grekova*, 1985, 135(11):42-3.

# SURGERY AND ANAESTHESIA AT THE DISTRICT HOSPITAL

A series of three handbooks  
that can help doctors acquire safe, standardized  
— and life-saving — surgical skills



This publication can be ordered from Distribution and Sales Unit, World Health Organization, 1211 Geneva 27, Switzerland. Telephone: (22) 791 2476; Fax: (22) 791 4857.